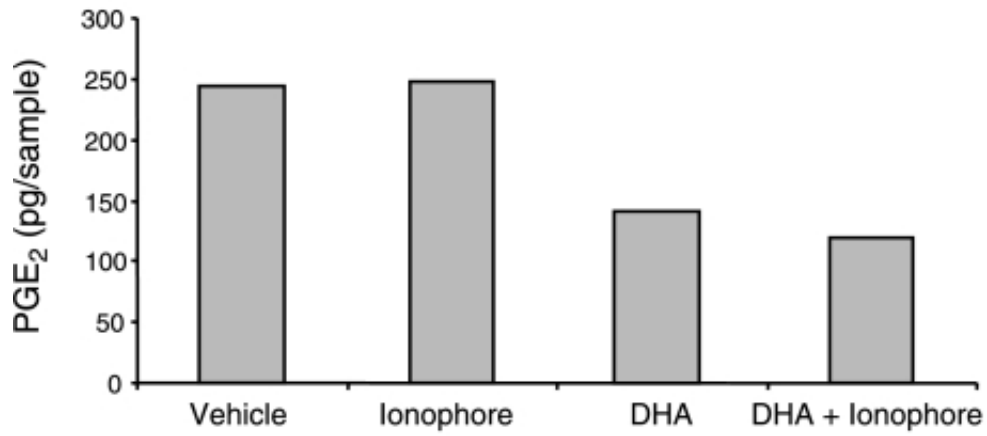
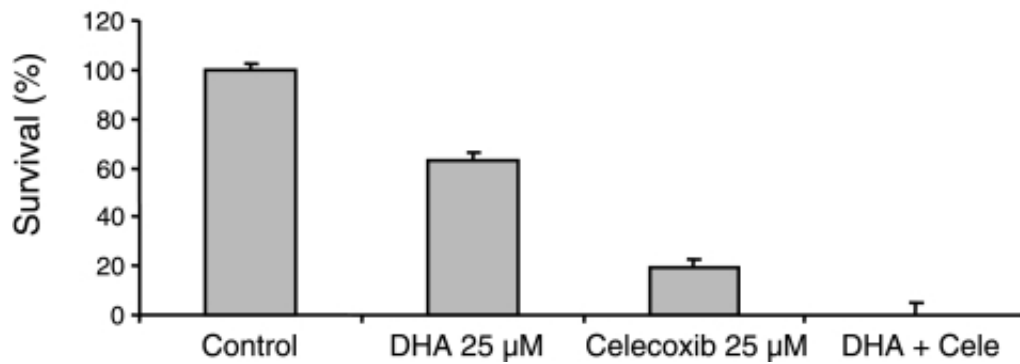


A**B**

in the laboratory with a similar tumor of neuroectodermal origin usually resistant to apoptosis with levels of medication that can be obtained in the brain
in the laboratory, not clinically, and not in medulloblastoma but suggestive.